



FINAL REPORT

Patient Information		Submitter Information	
Patient Name:	Patient, Test	Physician Name:	Test, Doc
Patient DOB:	01/01/2001	Patient Age:	22 Years
Patient Sex:	M	Physician Fax:	123-456-7890
Patient Code:	156695	Collection Date:	06/14/2023
		Received Date:	06/14/2023

Dermatopathology Report

Final Diagnosis

- A. BIOPSY - left anterior shoulder
SQUAMOUS CELL CARCINOMA, KERATOACANTHOMA TYPE
- B. BIOPSY - left superior laterateral upper back
BASAL CELL CARCINOMA, NODULAR TYPE

Pathologist, Signing
Dermatopathologist
06/20/2023

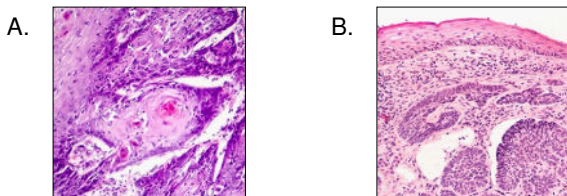
Clinical Information

- A. Morphology: 0.9 cm pink scaly papule DDX: Neoplasm of Uncertain Behavior vs. Squamous Cell Carcinoma
- B. Morphology: 0.8 cm pink papule DDX: Neoplasm of Uncertain Behavior vs. Basal Cell Carcinoma

Gross Description

- A. Received in 10% neutral buffered formalin is a segment of tissue measuring 1.0 x 0.8 x 0.2 cm.
- B. Received in 10% neutral buffered formalin is a segment of tissue measuring 0.7 x 0.6 x 0.1 cm.

Microscopic Description



- A. Neoplasm composed of a crater filled with keratinous material and pale eosinophilic keratinocytes showing focal atypia.
- B. Nodular collection of cells with scant cytoplasm and peripheral palisading of their nuclei is present within the dermis.

ICD Codes

C44.0, C44.91

Condensed CPT Codes

88305 x 2

(End of Report)